

(R)

(L)

Head  
4" Translation

- ⇒ Pain 7/10 or worse
- ⇒ Constant to some degree
- ⇒ Sleep difficult due to Pain

- 6.2° Pelvic Rot  
- 2.97" Hip Forward translation

8 Log Bolts

3- Surgeries

Fusions - L3/4  
L4/5  
L5/S1

Lumbar Extension Limited  
@ 10° = pain

Constant Pain  
\* Intensity varies  
\* Activity ↑ pain  
\* Must lie down for Relief

Issues:

- 1.) Hypertension
- 2.) Neuroptaly
- 3.) Weight Gain
- 4.) 3 failed Surgery

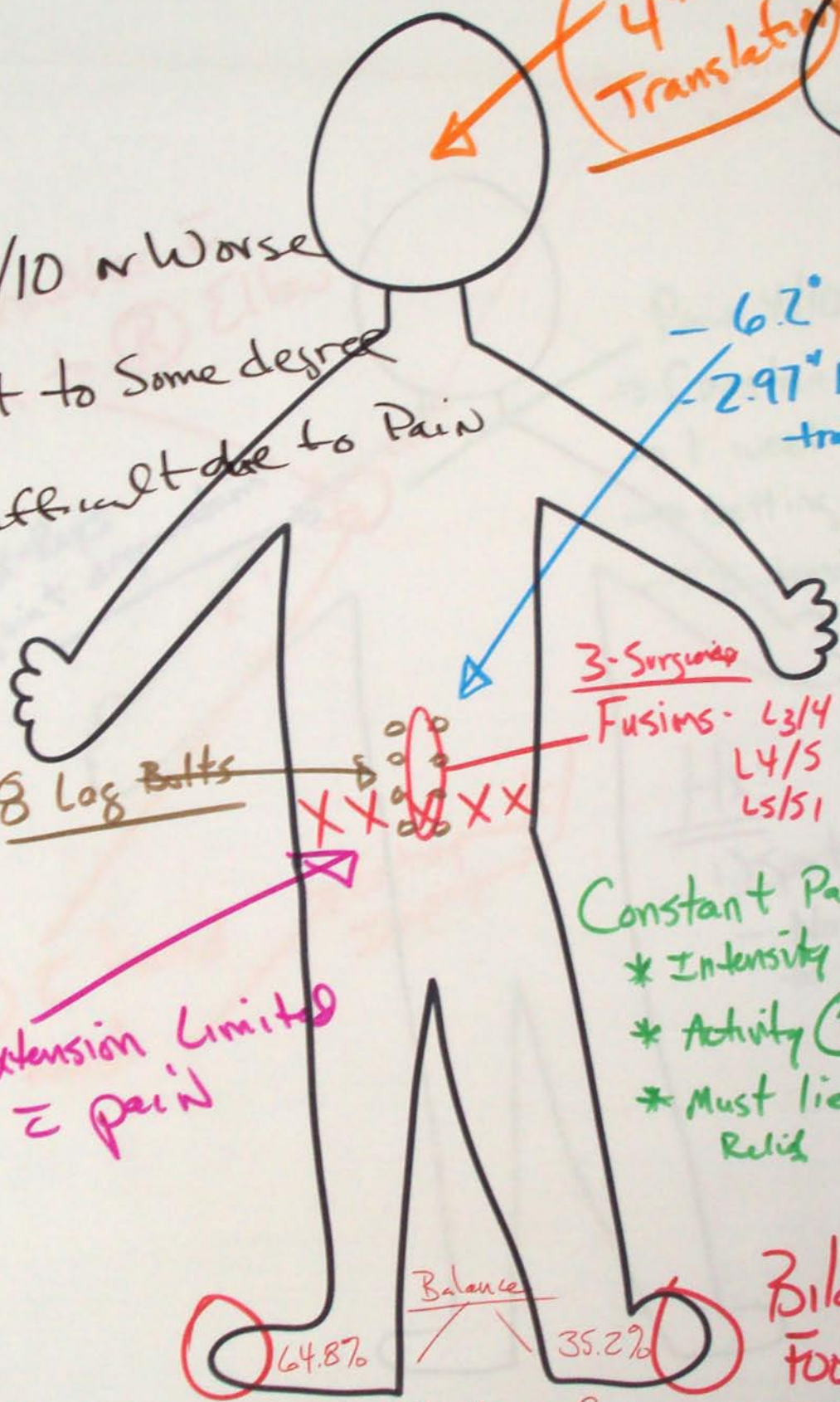
Balance

64.8%

35.2%

Gait Abnormal

Bilateral Foot drop





RIGHT

Hx: Injuring as young man  
Jumping off 40' cliff  
→ No treatment

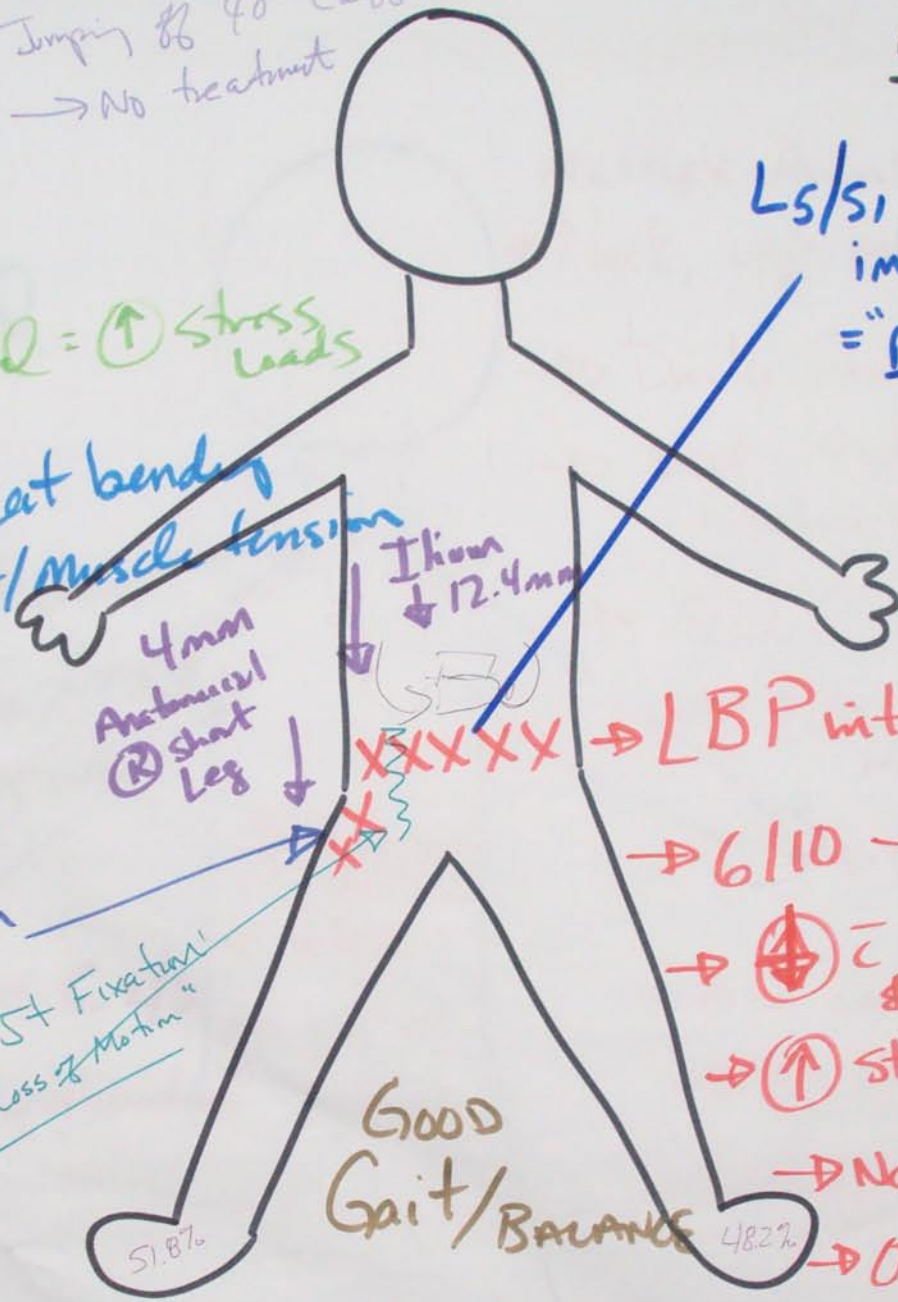
LEFT

POSTURE

→ Abnormal = ↑ Stress leads

ROM - ↓ Lat bending  
= ↑ Ligament/Muscle tension

L5/S1 facet imbrication = "pinned nerve"



4mm Anchoresal (R) short Leg

Ilium ↓ 12.4mm

→ LBP into (R) SI

→ 6/10 - FREQ

→ ↓ Activity & lying down

→ ↑ Standing/bending

→ Not changing

→ Onset 3 yrs Ago

mid (R) hip degeneration

(R) SI Jt Fixation "Loss of Motion"

GOOD Gait/BALANCE

Corrective Care

R.A.P

= Decompression  
Massage / ATM<sup>2</sup> / CMT

4mm (R) heel lift

Prognosis Good / Concern 3 yrs duration



RIGHT

① Stress due to Posture Abnormalities

X-Rays show Loss of Curve & disc loss and Arthritis

LEFT

1.) Bilateral Neck, Shoulder, Lowback, & Hip pain

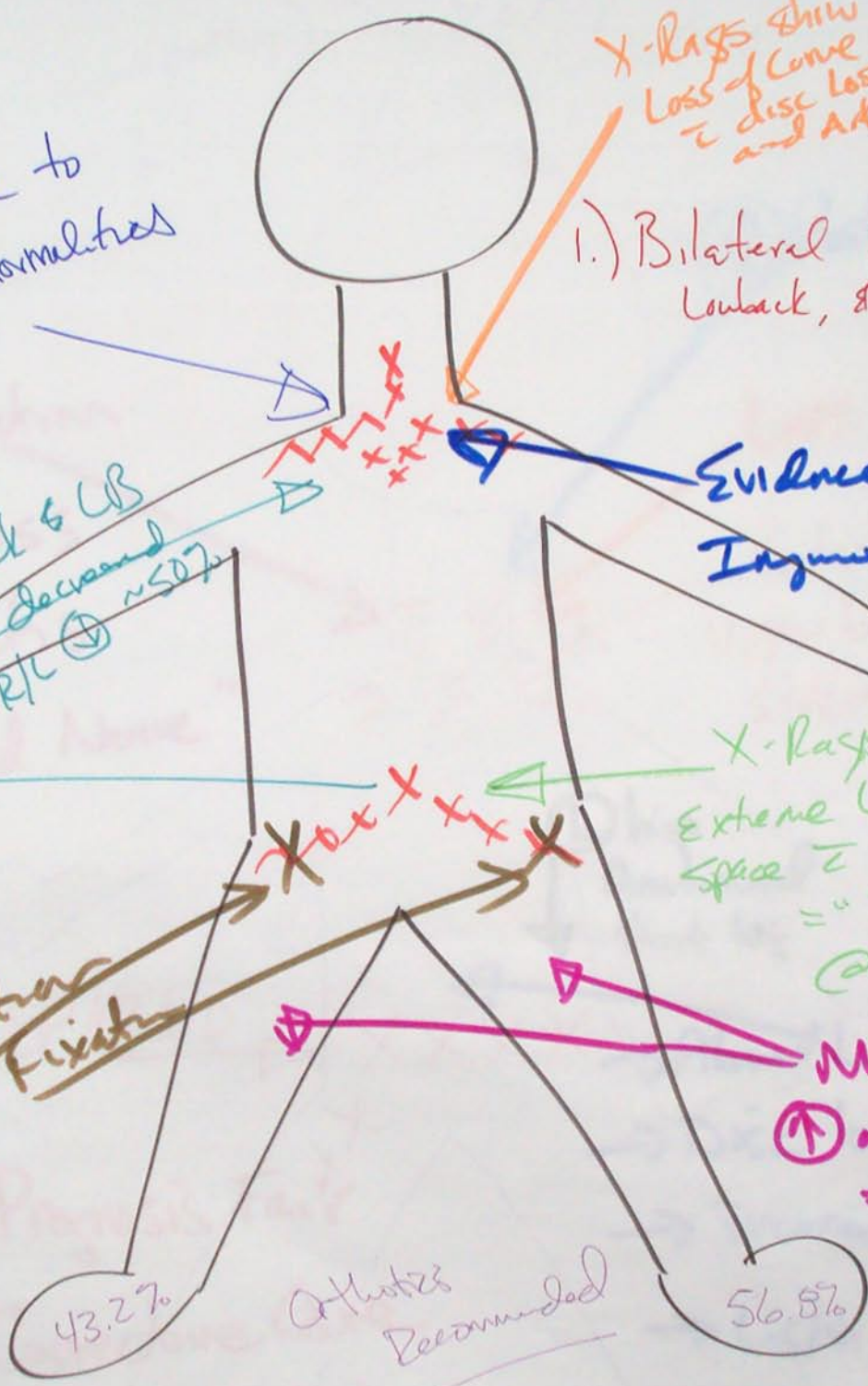Evidence of Ligament Injuries

COM ① Both Neck & LB  
→ Lumbar Extension decreased  
→ Cervical Rotation R/L ① ~50%

X-Rays show Extreme loss of disc space = IVF Narrowing = "Pinched Nerves" @ L4/5 & L5/S1

Hip Dysplasia  
= SI Jt Fixation

Muscle weakness  
① on ② leg / Thigh = Pinched Nerve



\* Corrective Care Recommended  
CMT / Orthotics / Rehab / Decompression

Prognosis: Fair /



(R)

(L)

(L) Anatomical Short leg  
6.3mm = (L) pelvic tilt

L4/L5 Disc  
Wedgeing, IVF  
Narrowing  
= Compression of  
Nerve Root

→ Lumbar Decompression  
→ ATM2 - Extension

6.3mm

Lumbar Extension  
⊕ Pain

Posture - Hip Anterior

(R) LBP/hip

Onset: 6 months Ago

pain → 5/10 Now  
7/10 Worst  
1/10 Best

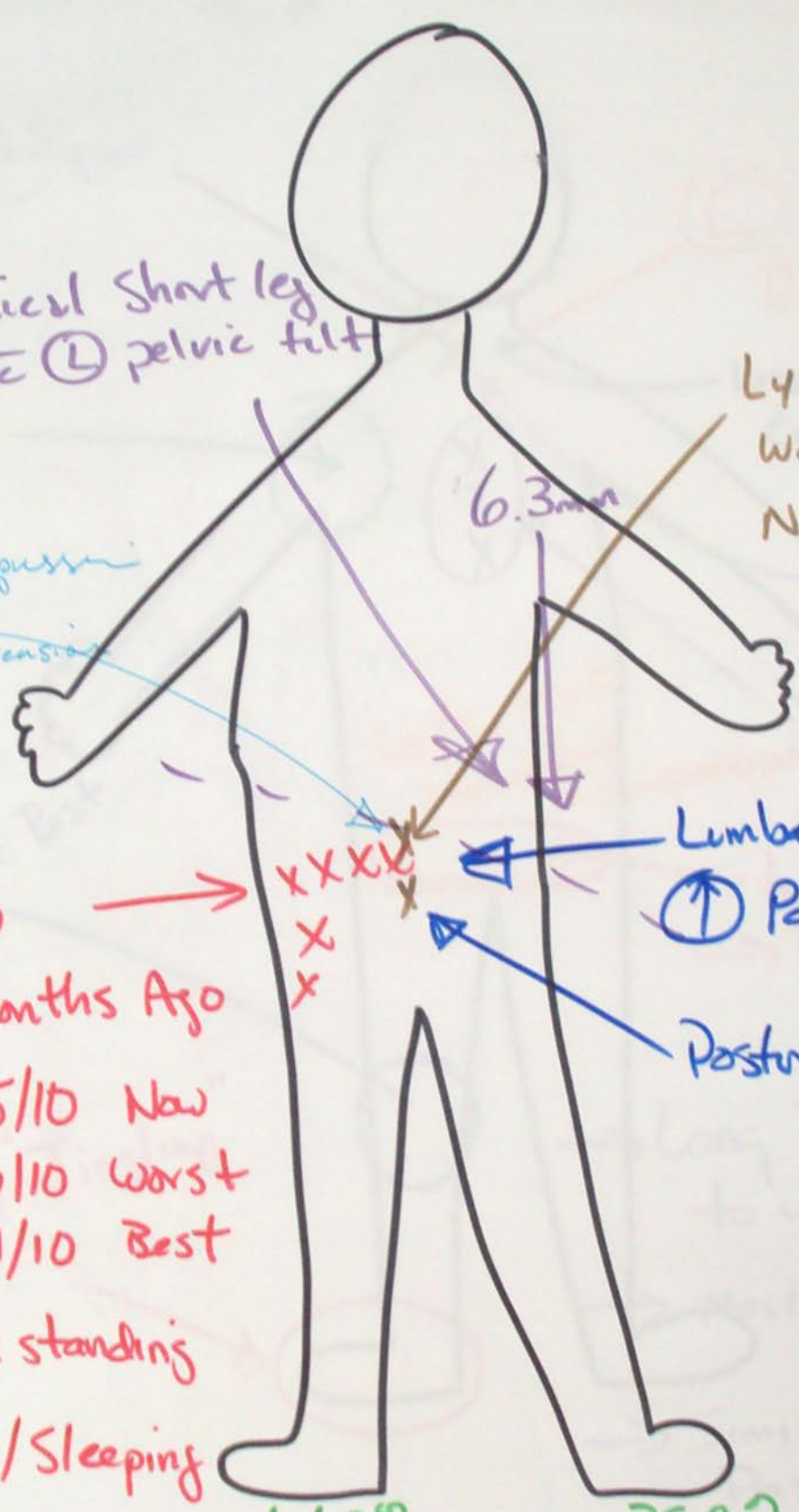\* Best when standing

↑ Sitting / Sleeping

64.2%

35.8%

Gait Abnormal  
→ orthotic & heel lift





RIGHT

LEFT

POSTURE:

→ Abnormal

ROM

- Loss of rotation
- tight ligaments/muscles & JT capsules

X-Rays

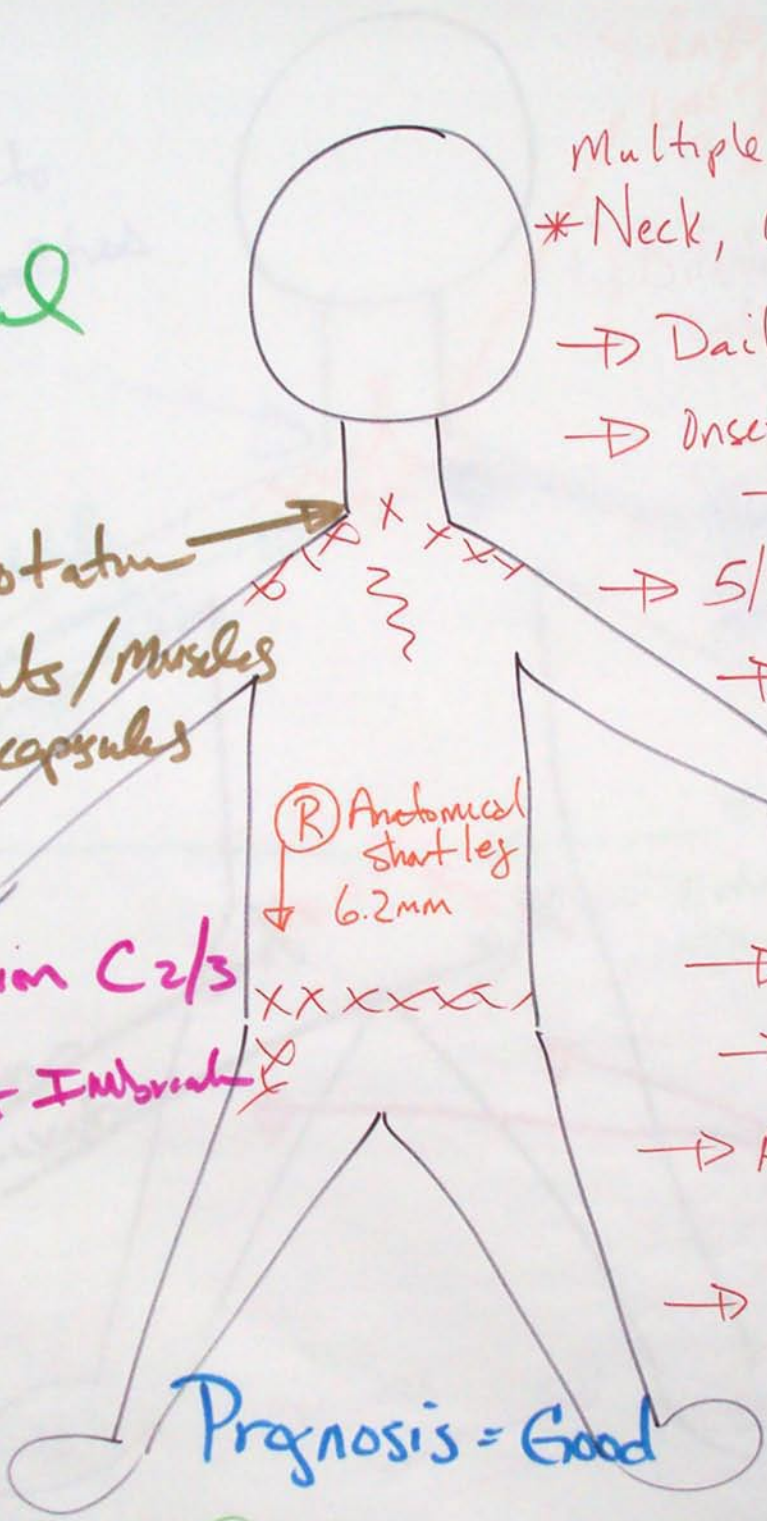- Cervical fusion C2/3
- L5/S1 facet Imbrication

R.A.P.

Prognosis = Good

Multiple Areas  
\* Neck, upperback, USP

- Daily Pain
- Onset: 4 wks Ago  
→ Similar in Past
- 5/10 (Constant to some)
- 2 wks Ago fell on treadmill
- Chiro helped in Past
- No corrective care
- No Imaging
- Activity ↑ Pain  
Biking etc
- Multiple traumas over lifetime  
Skiing etc



- Corrective Care  
CMT / Decompression / Home to  
ATM<sup>2</sup> / MASSAGE / Heel lift